Accepted Manuscript



Femoral tunnel widening after hamstring tendon autograft: Endobutton technique vs Double Cross-Pin technique

Mehdi Moghtadaei, Habib-o-lah Gorgani, Mehdi Abbasi, Ali Yeganeh, Iman Qomashi

PII: S0976-5662(18)30461-2

DOI: https://doi.org/10.1016/j.jcot.2019.02.001

Reference: JCOT 738

To appear in: *Journal of Clinical Orthopaedics and Trauma*

Received Date: 21 August 2018

Revised Date: 26 January 2019

Accepted Date: 2 February 2019

Please cite this article as: Moghtadaei M, Gorgani Hol, Abbasi M, Yeganeh A, Qomashi I, Femoral tunnel widening after hamstring tendon autograft: Endobutton technique vs Double Cross-Pin technique, *Journal of Clinical Orthopaedics and Trauma* (2019), doi: https://doi.org/10.1016/j.jcot.2019.02.001.

Original article

Femoral tunnel widening after hamstring tendon autograft: Endobutton technique vs Double Cross-Pin technique

Authors

Mehdi Moghtadaei[1], Habib-o-lah Gorgani[1], Mehdi Abbasi[1], AliYeganeh[1], Iman qomashi[1]

1) Department of orthopedic surgery, Rasool-e- Akram Hospital, Iran university of medical science, Tehran, Iran

Corresponding Author: AliYeganeh ; Department of orthopedic surgery, Rasool-e- Akram Hospital, Iran university of medical science, Tehran, Iran. Email address: Yeganeh471@yahoo.com.

Conflict of interest

All authors declare that they have no conflict of interest

Original article

Femoral tunnel widening after hamstring tendon autograft: Endobutton technique vs Double Cross-Pin technique

Abstract

Background/aim: An anterior cruciate ligament (ACL) rupture is a common sports-related injury requiring surgical intervention. With the advent of arthroscopically-assisted knee surgery, many graft fixation techniques for ACL have been developed. Femoral tunnel widening has been reported with a different incidence in various fixation techniques however its clinical significance is still not clear. We sought to compare femoral tunnel widening in patients undergoing arthroscopic anterior cruciate ligament (ACL) reconstruction with hamstring tendon autograft using either Endobutton or Double Cross-Pin technique.

Methods: In this prospective study, 40 patients with a diagnosis of unilateral, isolated ACL rupture were randomly assigned to either the Endobutton or Double Cross-Pin group. Patients were assessed for femoral tunnel widening using CT-scan and functional outcome was evaluated with international Knee Documentation Committee (IKDC) 2000 Subjective Knee Evaluation score and Lysholm score. Femoral tunnel diameter was determined based on intraoperative drill diameter and tunnel diameters on CT-scan performed every 6 months up to 18 months after surgery. Repeated measure analysis was used to compare the femoral tunnel diameter between two groups.

Results: All patients completed the study. The mean (±SD) age of Endobutton and Double Cross-Pin group was 29.75(±7.88), 31(±6.36), respectively. The mean change of femoral tunnel diameter for Endobutton group over 18 months was 3.05 and it was 2.34 for the Double Cross-Pin group. There was no statistically significant difference between two groups (p: 0.27). Also, the functional outcome was not significantly different between the two groups ($p > 0.05$)

Conclusion: Femoral tunnel widening after hamstring graft was not significantly different between Endobutton and Double Cross-Pin fixation techniques.

Keywords: Anterior cruciate ligament reconstruction; Endobutton technique; Double Cross-Pin technique; femoral tunnel widening; Hamstring tendon graft

Introduction

An anterior cruciate ligament (ACL) rupture is a common sports-related injury. While ACL repair is not recommended in all case, professional athletes or those who experience significant knee instability may opt for surgery [1]. Over the past decade with the introduction of arthroscopy numerous surgical techniques including different fixation methods with a variety of grafts have been used for reconstruction of ACL. Currently, Hamstrings tendon autograft along with Cross-pin or Endobutton fixation technique have been widely employed in an ACL reconstruction [2,3]. Femoral tunnel widening following an ACL reconstructive surgery has been reported since the mid-1990s [4]. The insufficient bone tissue to drill through for the new appropriate bone tunnel or troubles with the fixation of revision graft using the original bone tunnel are consequences of tunnel widening that could possibly complicate the ACL revision surgery [5]. The underlying cause of bone tunnel widening has not yet been established but it seems many factors including biomechanical, and biological processes contribute to it [6]. Endobutton and Cross-pin are two well-established methods for fixation of hamstrings graft from the femoral side, however, the direct comparison of these two methods with regards to femoral tunnel widening using radiological examination is limited to a handful of articles. In a study by Sabat et al. [6] authors reported significantly less femoral tunnel widening in Cross-pin group compared with Endobutton group after one year. In this study, we aimed to compare femoral tunnel widening after ACL reconstruction with hamstring autograft between Endobutton and Double Cross-Pin fixation methods.

Methods

Study design and patients

This prospective randomized trial was undertaken between 2016 and 2018 in Rasool-e-Akram Hospital affiliated with Iran University of Medical Sciences. The ethics committee of the university approved the study protocol. This study was also in accordance with the Helsinki

Declaration and its later amendments. Patients received enough information about each of the ACL reconstruction procedures, potential operative complications and success rate of each procedure. All patients who agreed to participate in this trial gave their written, informed consent authorizing the treatment and radiological examination. All operations were performed by one orthopedic surgeon. Patients included in this study if they satisfied the following criteria: age between 20 and 50 years old, unilateral, isolated ACL rupture confirmed clinically and by magnetic resonance imaging (MRI), normal contralateral knee, ACL rupture not older than 1 year. Exclusion criteria were concomitant ligament injury greater than grade two, meniscal repair, anatomical misalignment and cartilage defect greater than 2.

Intra-operative drill diameter was used as a baseline for radiological comparison. Previous studies have used this method for bone tunnel evaluation [7,8].

Radiological evaluation was performed every six months up to 18 months using CT-scan (Coronal and Sagittal view of the extended reconstructed knee) 16-slice multi-slice CT scan (MSCT) with 1mm slice thickness was used with post-processing multislab views on coronal and sagittal planes.

femoral tunnel diameter was measured at its greatest width perpendicular to the tunnel axis. Measured femoral tunnel diameters were averaged to have single femoral tunnel diameter (Figure 2).

Patients were randomly assigned to either Endobutton group (n=20) or Double Cross-Pin group (n=20) Using block randomization method with allocation ration of 1:1. Randomization was performed by an independent statistician who used computer-generated code to assign patients to each group.

Interventions

The senior author (M. M) performed all surgeries. Semitendinosus and gracilis tendons were harvested through a 5 cm oblique incision over the pes anserinus. The length of the acquired graft was usually about 30 mm. femoral tunnel was drilled as tight as possible corresponding to prepared graft diameter using standard instruments. Arthroscopically assisted ACL reconstruction was performed in all patients by single incision and any remnant of the ACL was shaved. In this study, anatomic single bundle ACL reconstruction method was adopted.

EndoButton CL (Smith & Nephew Endoscopy, Andover, MA) or Double Cross-Pin (Transfix [Arthrex, Naples, FL]) techniques are most widely used femoral fixation techniques for hamstrings grafts. In this study, EndoButton was performed using the same technique previously described in the literature[6]. In summary, the Femoral tunnel was drilled through the anteromedial portal while the knee was flexed at 120 degrees and the pre-tension graft was placed with 15-20 mm Endobutton CL device. Double Cross-Pin Technique was performed as outlined by Baumfeld et al with some difference. [7]. Briefly, the Femoral tunnel was drilled by using the anteromedial portal with 120-degree flexion of knee and footprint method with at least 2 mm bone tissue behind the tunnel. RigidFix Cross-Pin System was used to insert the graft. In RigidFix group, two PLAA, bioabsorbable cross pins are placed across the graft which had 30 mm long in the femoral bone tunnel. In both techniques, the graft was attached to the tibia using a BioRCI HA interference screw (Smith and Nephew) and a staple.

Rehabilitation protocol

Rehabilitation protocol was done under the supervision of a physiotherapist. With an aim of full extension restoration, weight-bearing exercises were started in the first week. During the third week, patients started active range of motion (ROM) exercises to reach 90° flexion. by the end of the sixth week, full flexion was achieved. At the third months, patients started jogging. Patients were allowed to return to full activity after six months. High-intensity sports activity was permitted after one year.

Clinical evaluation

Patients underwent a detailed functional assessment using the International Knee Documentation Committee (IKDC) 2000 Subjective Knee Evaluation score and Lysholm score [9] preoperatively and 18 months after surgery. Scores were compared within each group and also between two groups.

Statistical analysis

Statistical Analysis was carried out using SPSS 18.0. Continuous data were expressed as a mean± standard deviation and categorical values are reported as Frequency. Chi-square test was

used to compare categorical values. K-S test was performed to check for normal distribution of continuous date. Repeated measure analysis was conducted to interpret the data when appropriate. A *p*-value < 0.05 was considered a statistically significant.

Results

All patients completed the study. No patient was lost to follow-up. The mean (±SD) age of Endobutton and Double Cross-Pin group was 29.75(±7.88), 31(±6.36), respectively. There was no statistically significant difference between the mean ages of 2 treatment groups (*p*: 0.58). There were 13 males in the Endobutton group and 11 males in Double Cross-Pin group. The observed difference in gender between 2 groups was not statistically significant (*p*: 0.25). No postoperative complications including infection, deep vein thrombosis, nerve injury were noted and also no gross abnormalities such as flexion contracture or alignment were observed at the end of the study. Preoperative Lysholm score was on average 60 in Endobutton group and it was on average 62 in Double Cross-Pin Group. At the baseline visit, the mean score of IKDC was 59 and 60 in Endobutton and Double Cross-Pin groups respectively. There was no statistically significant difference between the two groups with respect to both Lysholm (*p*: 0.58) and IKDC (*p*:0.88) scores. IKDC score improved by a mean of 28 and 31 in Endobutton and Cross-pin group respectively and there was no statistically significant difference between the two groups (*p*: 0.62). Lysholm score also showed positive changes by a mean of 24 and 26 in Endobutton and Double Cross-pin group respectively. No significant difference was noted between two groups with respect to the mean change of Lysholm scores (*p*: 0.56).

There was no correlation between Tunnel widening and function outcome evaluated by both Lysholm and IKDC scores (*p*: 0.65).

The mean femoral tunnel diameters and the mean difference between two groups at the baseline and follow up visits are depicted in Table 1. The mean change of femoral tunnel diameter for Endobutton group over 18 months was 3.05 and it was 2.34 for the Double Cross-Pin group. By the general linear model, the repeated-measures analysis was carried out based on femoral tunnel diameter, and it revealed no statistically significant difference between two fixation techniques after 18 months (*p*: 0.27) (Figure 2).

Discussion

Femoral tunnel widening has been described as an adverse event of arthroscopic ACL reconstruction. Compared to other grafts, hamstring tendon graft has been associated with more frequent, greater tunnel enlargement, however, no correlation has been reported between knee functional outcome and femoral tunnel widening. Femoral tunnel widening may result in complications in ACL revision surgery including the need for bone graft for correcting widened bone tunnel. The primary finding of this study is that the femoral tunnel widening is not significantly different between the two treatment groups. Our findings are in contrast to the findings reported by Sabat and his colleagues [6]. In their study Sabat et al. Compared Endobutton to Cross-pin technique in 34 patients suffering from unilateral ACL. Patients were followed for 1 year and they were evaluated for femoral tunnel widening at 2 weeks, 3 months and 6 months after ACL reconstruction using CT-scan at coronal and sagittal sections. Authors reported that there was a significant difference in femoral tunnel diameter between two groups at both coronal and sagittal sections. Aperture and midway diameters in femoral tunnel showed a statistically significant difference. They concluded Cross-pin method was superior to Endobutton fixation technique in terms of femoral tunnel widening. In another study in 60 patients in 2001 [10], authors compared anatomical fixation technique with extra-cortical fixation technique and the plain radiography was done at 2 days, 6 months and 24 months postoperatively. They reported anatomical method had more significant femoral tunnel area compared to the extra-cortical method. In a study by Peyrache et al. [11] tunnel diameter increased after 3 months. No changes in tunnel diameter were noticed between 3 months and 2 years, and after 3 years tunnel diameter decreased. In line with this study, Fink et al. [12] and Harris et al. [13] documented bone tunnel widening within the first 6 weeks after ACL reconstruction. Since bone tunnel enlargement beyond the first year of operation has not reported, the design of our study with 1 year follow-up is supposedly ideal for evaluating for femoral tunnel widening. L'Insalata et al. [14] reported femoral tunnel widening as well. On AP and lateral view radiography the mean percentage increases were 30.2% (±17.2%) and 28.1% (±14.7%) respectively. Jansson et al. [15] reported an average 33% enlargement of femoral on AP radiography, while. Raffaele et al. [16] demonstrated a slight femoral (3 %) bone tunnel enlargement following ACL reconstruction with hamstring graft. Our results depicted a 37% and 28% increase in femoral tunnel diameter in Endobutton and Cross-pin groups respectively.

As with other studies, functional outcome was not significantly different between the two fixation methods we used. Also, implications of femoral tunnel widening for the clinical outcome is not clear. Consistent with previous findings, we did not find any correlation between tunnel widening and functional outcome [17,10,18]. In a review, Hoher et al. [19] discussed the possible theory about the etiology of bone tunnel enlargement. They speculated that Bungee effect is the underlying mechanism for the widening of the bone tunnel and they also concluded anatomical initial graft fixation could potentially prevent this event. There are limitations to this study which could also account for the difference between our finding and the results of previous studies. Our study population was small and we followed our patients for only one year however significant tunnel enlargement has not been shown beyond 1 year. Additionally the method we used to determine the femoral tunnel diameter was different from previous studies. We used different methods to create a femoral tunnel in both groups; although we chose the best method for each fixation technique. Also worth noting our finding could be partially due to the fact that our rehabilitation protocol which was started in first week theoretically could have prevented femoral tunnel enlargement.

More clinical trials with a larger study population and shorter follow-up intervals are required to evaluate the current findings regarding bone tunnel widening in patients undergoing ACL reconstruction. Moreover, more studies are needed to assess the femoral tunnel widening in patients going through ACL reconstruction revision surgery.

Conclusion

Femoral tunnel widening after hamstring graft was not significantly different between Endobutton and Cross-pin fixation techniques.

Compliance with ethical standards

Ethical approval was obtained from the ethics committee of Iran University of Medical Sciences.

This study was also in accordance with the Helsinki Declaration and its later amendments and prior to entering the study patients gave their informed consent to participate in this study.

Declaration of interest statement

All authors declare that they have no conflict of interest

References

1. Gordon M (2004) Anterior cruciate ligament injuries. Orthopaedic knowlegde update: sports medicine:169-181
2. Weiler A, Richter M, Schmidmaier G, Kandziora F, Südkamp NP (2001) The EndoPearl device increases fixation strength and eliminates construct slippage of hamstring tendon grafts with interference screw fixation. Arthroscopy 17 (4):353-359
3. Moghtadaei M, Farahini H, Enayati S, Motalebi M, Gorgani H-o-L (2017) Arthroscopic Meniscal Repair in Outside-In Technique: A Clinical and Paraclinical Study. Shafa Orthopedic Journal (In Press)
4. Fahey M, Indelicato PA (1994) Bone tunnel enlargement after anterior cruciate ligament replacement. The American journal of sports medicine 22 (3):410-414
5. Fauno P, Kaalund S (2005) Tunnel widening after hamstring anterior cruciate ligament reconstruction is influenced by the type of graft fixation used: a prospective randomized study. Arthroscopy 21 (11):1337-1341
6. Sabat D, Kundu K, Arora S, Kumar V (2011) Tunnel widening after anterior cruciate ligament reconstruction: a prospective randomized computed tomography–based study comparing 2 different femoral fixation methods for hamstring graft. Arthroscopy 27 (6):776-783
7. Baumfeld JA, Diduch DR, Rubino LJ, Hart JA, Miller MD, Barr MS, Hart JM (2008) Tunnel widening following anterior cruciate ligament reconstruction using hamstring autograft: a comparison between double cross-pin and suspensory graft fixation. Knee Surgery, Sports Traumatology, Arthroscopy 16 (12):1108-1113
8. Siebold R (2007) Observations on bone tunnel enlargement after double-bundle anterior cruciate ligament reconstruction. Arthroscopy 23 (3):291-298
9. Tegner Y, Lysholm J (1985) Rating systems in the evaluation of knee ligament injuries. Clinical orthopaedics and related research (198):43-49
10. Buelow J-U, Siebold R, Ellermann A (2002) A prospective evaluation of tunnel enlargement in anterior cruciate ligament reconstruction with hamstrings: extracortical versus anatomical fixation. Knee Surgery, Sports Traumatology, Arthroscopy 10 (2):80-85
11. Peyrache M, Djian P, Christel P, Witvoet J (1996) Tibial tunnel enlargement after anterior cruciate ligament reconstruction by autogenous bone-patellar tendon-bone graft. Knee Surgery, Sports Traumatology, Arthroscopy 4 (1):2-8
12. Fink C, Zapp M, Benedetto KP, Hackl W, Hoser C, Rieger M (2001) Tibial tunnel enlargement following anterior cruciate ligament reconstruction with patellar tendon autograft. Arthroscopy 17 (2):138-143
13. Harris NL, Indelicato PA, Bloomberg MS, Meister K, Wheeler DL (2002) Radiographic and histologic analysis of the tibial tunnel after allograft anterior cruciate ligament reconstruction in goats. The American journal of sports medicine 30 (3):368-373
14. L'Insalata JC, Klatt B, Fu FH, Harner CD (1997) Tunnel expansion following anterior cruciate ligament reconstruction: a comparison of hamstring and patellar tendon autografts. Knee Surgery, Sports Traumatology, Arthroscopy 5 (4):234-238
15. Jansson K, Harilainen A, Sandelin J, Karjalainen P, Aronen HJ, Tallroth K (1999) Bone tunnel enlargement after anterior cruciate ligament reconstruction with the hamstring autograft and endobutton fixation technique A clinical, radiographic and magnetic resonance imaging study with 2 years follow-up. Knee Surgery, Sports Traumatology, Arthroscopy 7 (5):290-295

16. Iorio R, Vadalà A, Argento G, Di Sanzo V, Ferretti A (2007) Bone tunnel enlargement after ACL reconstruction using autologous hamstring tendons: a CT study. International orthopaedics 31 (1):49-55
17. Barrett GR, Papendick L, Miller C (1995) Endobutton button endoscopic fixation technique in anterior cruciate ligament reconstruction. Arthroscopy 11 (3):340-343
18. Fauno P, Kaalund S (2005) Tunnel widening after hamstring anterior cruciate ligament reconstruction is influenced by the type of graft fixation used: a prospective randomized study. Arthroscopy: The Journal of Arthroscopic & Related Surgery 21 (11):1337-1341
19. Höher J, Möller H, Fu F (1998) Bone tunnel enlargement after anterior cruciate ligament reconstruction: fact or fiction? Knee Surgery, Sports Traumatology, Arthroscopy 6 (4):231-240

Table 1. Means and standard deviations of femoral tunnel diameters in Endobutton and Double Cross-Pin group

	Endobutton	***Double Cross-Pin***	***Mean Difference***
Baseline	8.22 (±0.48)	8.35 (±0.30)	-0.13
6 months	9.75 (±0.77)	9.54 (±0.8)	0.21
12 months	10.76 (±1.02)	10.38 (±0.9)	0.38
18 months	11.27 (±1.13)	10.69 (±0.9)	0.58

Figure 1. Example of study patients CT-scan with Digital measurements

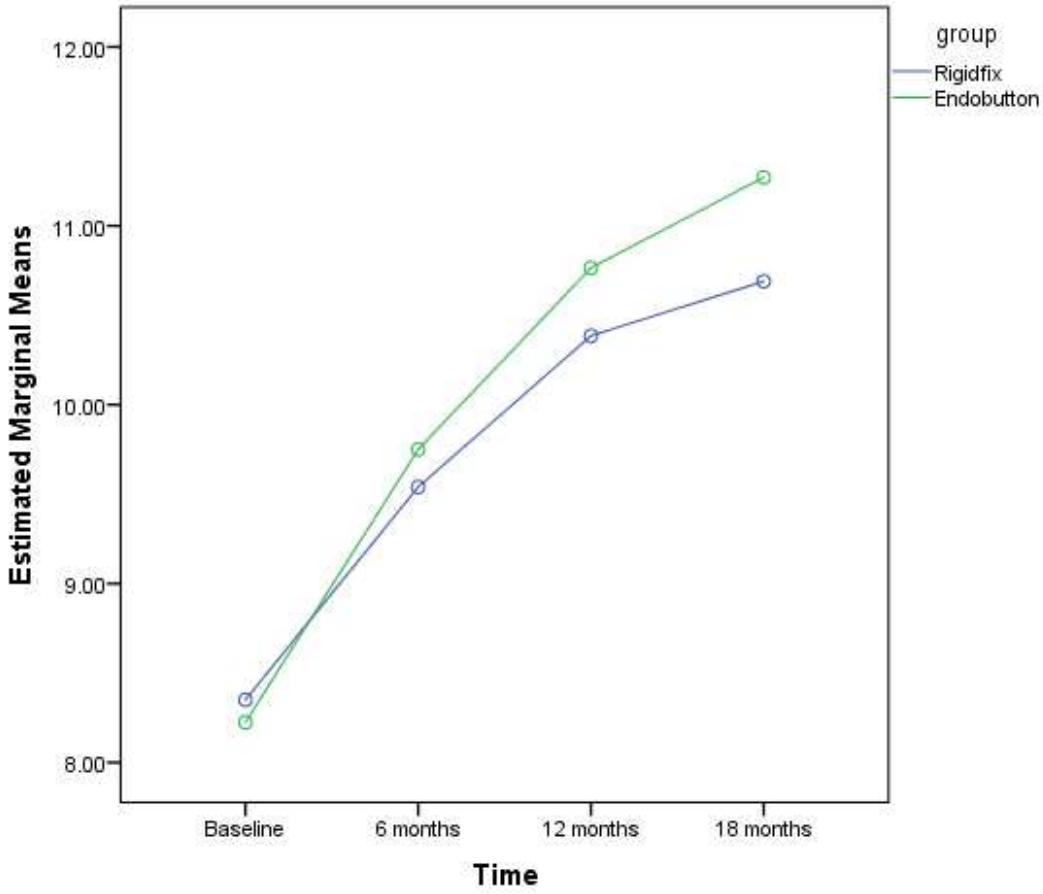

Figure 2. Mean changes in Femoral Tunnel Diameter from baseline in the Endobutton and the Double Cross-Pin group.